

cirrhosis

Cirrhosis is the eighth leading cause of death by disease, killing about 25,000 people each year. In cirrhosis of the liver, scar tissue replaces normal, healthy tissue, blocking the flow of blood and preventing the liver from working as it should.

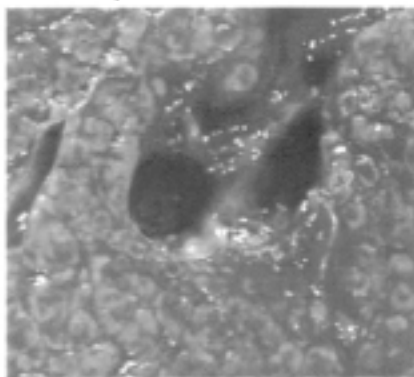
Cirrhosis has many causes. In the United States, chronic alcoholism and hepatitis C are the most common causes. Inherited conditions that can result in cirrhosis include alpha-1 antitrypsin deficiency, hemochromatosis, Wilson's disease, galactosemia, and glycogen storage disease. Nonalcoholic steatohepatitis (NASH), blocked bile ducts, drugs, toxins, and infections and repeated bouts of heart failure with liver congestion can also lead to cirrhosis.

Symptoms of cirrhosis can range from no symptoms, whatsoever, to chronic weakness and fatigue, loss of appetite, nausea, and weight loss. Complications caused by cirrhosis are quite varied because good liver function is central to metabolic processes.

Conventionally, cirrhosis is confirmed with a liver biopsy. A needle is inserted into the abdomen, generally with the aid of ultrasound. A liver tissue sample is obtained, stained and examined. For some the procedure is fairly straightforward with few side effects. Others report that the biopsy area is very tender for a few days and still some patients refuse to have the procedure, because they consider it too invasive. Knowing whether or not a patient has cirrhosis is important to the prognosis for that patient. But since the procedure is declined by some patients, investigators have sought ways to predict cirrhosis using other methods. Some of these helpful diagnostic procedures include specialized MRI, computerized axial tomography (CAT) scan, or ultrasound. Or a physician might look at the liver using a laparoscope, an instrument inserted through the abdomen that relays pictures back to a computer screen. In most of these procedures an iron load can be detected and estimated to

some degree but damage such as cirrhosis cannot be determined.

Canadian investigators Beaton, Guyader, Deugnier, Moirand, Chakrabarti, and Adams recorded 16 clinical and laboratory variables in



Liver tissue sample: Cirrhosis

193 Canadian C282Y homozygous patients. Each patient had a liver biopsy to determine the presence or absence of cirrhosis. From the data, these investigators devised an index for the noninvasive prediction of cirrhosis. They tested their index on participants of the study and found it to accurately predict cirrhosis in an average of 81%* patients. The index is derived from a combination of serum ferritin greater than or equal to 1,000ng/mL, platelet levels of $200 \times 10^9/L$ or less, and AST levels above the upper limit of normal (10-40 IU/L). Physicians might consider this index prior to ordering a liver biopsy in their C282Y homozygous patients.

Investigators Morrison, Brandhagen, Phatak, Barton, Krawitt, El-Serag, Gordon, Galan, Tung, Ioannou and Kowdley studied 182 US patients with hemochromatosis. They concluded that patients with HHC and serum ferritin levels less than 1000ng/mL are unlikely to have cirrhosis. They further stated that liver biopsy to screen for cirrhosis may be unnecessary in such patients, regardless of age or serum liver enzyme levels.

References:

Morrison, Brandhagen, Phatak, Barton, Krawitt, El-Serag, Gordon, Galan, Tung, Ioannou and Kowdley "Serum ferritin level predicts advanced hepatic fibrosis among US patients with phenotypic hemochromatosis" *Annals of Internal Medicine* 131 (2003): 627-33.

Beaton, Guyader, Deugnier, Moirand, Chakrabarti, and Adams. "Noninvasive prediction of cirrhosis in C282Y-linked hemochromatosis." *Hepatology*. 36 (2002):673-8.

Was Beethoven's Cirrhosis Due to Hemochromatosis?

According to his medical history, Ludwig von Beethoven suffered from recurrent obscure abdominal pain, arthritis, pigmented skin and had a family history of liver disease. He died at age 56 and an autopsy revealed hepatic cirrhosis and pancreatitis. We all know that Ludwig von Beethoven was deaf; what might not be known is that 20-30% of patients with hemochromatosis suffer hearing loss.

The Official Autopsy

Protocol Concerning the Post-Mortem Examination That Was Carried Out on the Body of Master Ludwig van Beethoven.

The body of the dead man showed intense wasting and scattered black petechiae especially in the extremities, the abdomen was distended and swollen with fluid and its skin was stretched. The thoracic cavity and its contents were normal. The abdominal cavity was filled with four measures of rust-coloured fluid. The liver was reduced to half its normal size, was like leather, hard and in colour slightly bluish-green and throughout its substance were nodes each about the size of a bean.

All its vessels were greatly narrowed, considerably thickened and devoid of blood. The gall-bladder contained a dark-coloured fluid and in this was a great deal of sediment like gravel. The spleen was greater than twice the normal size, hard, and when it came into view blackish in colour. In the same way the pancreas was found to be larger and firmer than normal, its excretory duct allowed the quill of a goose to be passed. The stomach together with the intestines were greatly distended with air.

Private post-mortem examination carried out on 27 March 1827.

Dr. Johann Wagner
Assistant Pathology Museum
(translated by Dr. John Horan of Melbourne)
Source: Peter J. Davies, MD, FRACP, MRCP
Was Beethoven's Cirrhosis Due to Hemochromatosis? *Renal Failure*, 17 (1995): 77-86.

Bonkovsky HL, Lambrecht RW. Iron-induced liver injury. *Clin Liver Dis* 4 (2000) 409-29 vi-vii

Witte D, Crosby W, Edwards C, Fairbanks V, Mitros F, Hereditary Hemochromatosis *Clinica Chimica Acta* 1996, 245:139-200

<http://www.niddk.nih.gov/health/digest/pubs/cirrhosi/cirrhosi.htm>